



ISSN: 2091-2749 (Print)
2091-2757 (Online)

Correspondence

Dr. Sanjit Karki
Lecturer, Department of
Medicine, Patan Academy of
Health Sciences, Lalitpur,
Kathmandu, Nepal
Email: sanjitkarki@pahs.edu.np

Peer Reviewed By

Dr. Jay N Shah
Patan Academy of Health
Sciences

Peer Reviewed By

Dr. Ashis Shrestha
Patan Academy of Health
Sciences

Histopathological findings of renal biopsy in systemic lupus erythematosus

Sanjit Karki,¹ Roshan Shrestha,¹ Buddhi Poudyal,³ Bimal Pandey,¹
Nora Ranjitkar,² Yubaraj sharma,³ Gyan Krishna Kayastha³

¹Lecturer, ²Assistant Professor, ³Associate Professor, Department of
Internal Medicine, Patan Academy of Health Sciences, Lalitpur, Nepal

ABSTRACT

Introductions: Classifying morphological pattern of renal involvement is important in systemic lupus erythematosus (SLE) for definitive treatment and prognosis. This study aim to analyse the histopathological pattern of glomerular in SLE patients.

Methods: This was a retrospective chart review of patients diagnosed with SLE who had renal biopsy during October 2013 to September 2015 at Patan Hospital.

Results: There were 38 patients of SLE. Antinuclear antibody (ANA) was positive in all patients 38 (100%), Anti-dsDNA seen in 18 (47.4%). Active urinary sediment & proteinuria was seen 25 (65.8%) patients and proteinuria in 13 (34.2%) patients. Histopathological patterns were of glomerular involvement was, ISN Class II in 2 (5.3%), Class III in 2 (5.3%), class IV 20 (52.5%), class V in 6 (15.8%) and mixed IV–V in 8 (21.1%).

Conclusions: The diffuse proliferative lupus nephritis (ISN Class IV) was the most common pattern of lupus nephritis encountered in our study followed by mixed pattern (ISN class IV&V) and membranous lupus nephritis (ISN class IV).

Keywords: histopathology, lupus nephritis, renal biopsy, systemic lupus erythematosus

INTRODUCTIONS

Systemic lupus erythematosus (SLE) is a chronic inflammatory disease affecting multiple organs. The reported prevalence of SLE is 20 to 150 cases per 100,000.^{1,2} In women, prevalence rates vary from 164 (white) to 406 (African American) per 100,000.²

Renal involvement is common in SLE. An abnormal urinalysis with or without an elevated plasma creatinine concentration is present in a large proportion of patients at the time of diagnosis of lupus nephritis. This may eventually develop in up to 75 percent of patients with a diagnosis of SLE.³ It is crucial to obtain morphological histopathological pattern to decide the severity of disease, treatment and prognosis.

The objective of this study was to assess the occurrence of different glomerular histopathological pattern of renal biopsy in patients with SLE managed at our hospital.

METHODS

This was a retrospective chart review of SLE patients aged 16 years or more admitted in the department of Internal Medicine, Patan Hospital, Patan Academy of Health Sciences, Lalitpur, Nepal, during October 2013 to September 2015. Diagnosis of SLE was based on four or more of the clinical criteria of the American Rheumatism Association.⁴ Patients who underwent renal biopsy were included.

Clinical and laboratory data were collected from inpatient chart. Renal biopsy was done with ultrasound guide. The histopathology grading of lupus nephritis (LN) was based on International Society of Nephrology (ISN) pathologic classification⁵ (revised version of old World Health Organization) as follows: Minimal mesangial LN (class I), Mesangial proliferative LN (class II), Focal proliferative LN (class III), Diffuse proliferative LN (class IV), Membranous LN (class V) and Advanced sclerosing LN (class VI).

Statistical Package for Social Sciences (SPSS) version 17 was used for descriptive analysis. The institutional review committee of PAHS approved the study.

RESULTS

There were 38 SLE patients, female 34 (89.5%) and male 4 (10.5%). Mean age at the onset of disease was 26.3 ± 7.9 years and 16 (42.1%) were in age group 21- 30, Figure 1.

Anaemia was seen in 28 (73.6%) patients. Mean 24 hour urinary protein was 2939.42 mg (SD \pm 2096.02). The ANA was positive in all 38 (100 %) and Anti-dsDNA in 18 (47.4%) patients, Table 1. Active urinary sediment with proteinuria was seen in 25 (65.8%) and proteinuria alone in 13 (34.2%). The histopathological pattern of class IV LN was seen in 20 (52.5%), Table 2.

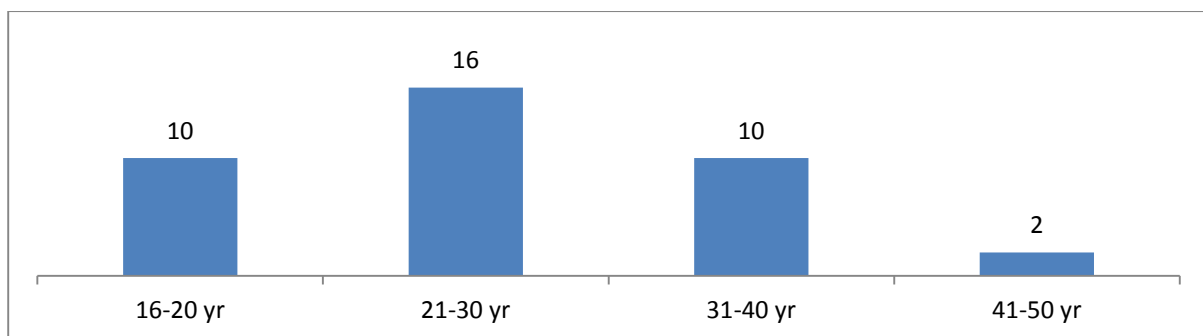


Figure 1. Age of presentation of lupus nephritis (LN) in systemic lupus erythematosus (SLE) patients (n=38)

Table 1. Clinical and laboratory characteristics of patients with SLE (n=38)

| Variable | mean \pm SD (percentage) |
|-----------------------------|----------------------------|
| Malar Rash | 30 (78.9%) |
| Discoid Rash | 8 (21.1%) |
| Photosensitivity | 28 (73.7%) |
| Oral Ulcer | 12(31.6%) |
| Arthritis | 26(68.5%) |
| Serositis | 12(31.6%) |
| Anemia | 28 (73.3 %) |
| 24 hr Urinary Protein (mg) | 2939.42 \pm 2 2096.02 |
| ESR (mm) | 80.36 \pm 34.87 |
| Anti-dsDNA | 18(47.4%) |
| ANA | 38(100%) |

Note: SD- standard deviation

Table 2. The histopathology grading of Lupus Nephritis (n=38) according to ISN Classification (International Society of Nephrology and Renal Pathology Society)

| Histopathological Class | Number (%) |
|---|------------|
| Class II: Mesangial Proliferative Lupus Nephritis | 2 (5.3%) |
| Class III: Focal Lupus Nephritis | 2 (5.3%) |
| Class IV: Diffuse Lupus Nephritis | 20 (52.6%) |
| Class V: Membranous Lupus Nephritis | 6 (15.8%) |
| Mixed pattern (Class IV & V) | 8 (21.1%) |

DISCUSSIONS

The predominant histopathological pattern was class IV in our study which is comparable with other studies.⁶⁻⁹ In our study, Class I was not observed. Dhakal et al¹⁰ in a Nepalese study have reported more common findings of class I & II in 13.5% and 35.5% respectively. Class I is the initial stage of lupus nephritis where abnormal renal changes may not be

apparent³ and renal biopsy is mostly performed in more active disease.

Majority of patients in this study were female. This findings is similar to other studies of SLE that have shown a predominance in females.^{11,12} The mean age at presentation was 26.26 \pm 7.9 years which is similar to earlier reported series.^{9,13} Austin et al. and Esdaile et al. have reported young age (<23 years) as one

of the indicators associated with increased rate of renal failure and a more rapidly progressive course.^{11,14}

The cutaneous lesions including malar rash, discoid rash, and photosensitivity were seen in 78.9%, 21.1%, and 73.7% of patients respectively. The data were similar to previous study done in Nepal.¹⁰ However, we noticed great variation in incidence, clinical heterogeneity and severity of disease due to environmental, cultural and genetic variability in the various ethnic and racial group when comparing with other studies.^{8,15}

In our study anaemia was observed in majority of patients 73.3% which is a frequent occurrence in SLE, affecting most patients at some time in the course of their disease.⁹

Multiple mechanisms contribute to the development of anaemia, including inflammation, renal insufficiency, blood loss, dietary insufficiency, medications, haemolysis, infection, hypersplenism, myelofibrosis, myelodysplasia, and aplastic anaemia that is suspected to have an autoimmune pathogenesis.⁹

Almost all of our patients with SLE had positive ANA, similar to other studies.^{10,16,17} The Anti dsDNA which is considered specific for SLE and marker of disease activity was seen in 47.4% of our patients which is slightly lower than other studies.^{10,15} We didn't observe advance stage of class VI possibly because all patients were in active state. The prevalence of different histopathological pattern reported in literature is compared in Table 3.

TABLE 3. Histopathological class of Lupus Nephritis in different series

| ISN class | Dhaka ¹⁰ n=37 | Kafle ⁶ n=40 | Shobha ⁸ n=3 ² | Gomaa ⁹ n=148 | Satirapoj ⁷ n=244 | Present study n=38 |
|-------------|-----------------------------|----------------------------|---|-----------------------------|---------------------------------|-----------------------|
| Class I | 13.5% | 2.5 % | 0 | 0 | 0 | 0 |
| Class II | 35.5% | 10 % | 28.1 % | 12.8 % | 2.8% | 5.3% |
| Class III | 24.3% | 12.5 % | 21.9 % | 8.8% | 15.5% | 5.3% |
| Class IV | 18.9% | 52.5 % | 40.6 % | 51.4% | 69.6% | 52.5% |
| Class IV &V | 0 | 5 % | 0 | 0 | 0 | 21.1% |
| Class V | 5.4% | 2.5 % | 9.4 % | 23% | 17.6% | 15.8% |
| Class VI | 2.7% | 2.5 % | 0 | 4% | 0 | 0 |

The limitation of our study was lack of sub grouping in class III and class IV which gives idea on activity and chronicity of disease. This study also did not look into other forms of renal involvement like tubulointerstitial nephritis and vascular disease.

CONCLUSIONS

We observed diverse histopathological pattern of Lupus Nephritis, with diffuse proliferative type (ISN Class IV) being most common

followed by mixed pattern (class IV&V) and membranous lupus nephritis (class IV).

REFERENCES

1. Lawrence RC, Helmick CG, Arnett FC, Deyo RA, Felson DT, Giannini EH, et al. Estimates of the prevalence of arthritis and selected musculoskeletal disorders in the United States. *Arthritis Rheum.* 1998;41(5):778-99.
2. Chakravarty EF, Bush TM, Manzi S, Clarke AE, Ward MM. Prevalence of

- adult systemic lupus erythematosus in California and Pennsylvania in 2000: estimates obtained using hospitalization data. *Arthritis Rheum.* 2007;56(6):2092-4.
3. Bomback AS, Appel GB. Diagnosis and classification of renal disease in systemic lupus erythematosus. In: UpToDate, Glasscock RJ, editor. Waltham, MA: UpToDate; 2017.
 4. Hochberg MC. Updating the American College of Rheumatology revised criteria for the classification of systemic lupus erythematosus. *Arthritis Rheum.* 1997;40(9):1725.
 5. Weening JJ, D'Agati VD, Schwartz MM, Seshan SV, Alpers CE, Appel GB, et al. The classification of glomerulonephritis in systemic lupus erythematosus revisited. *J Am Soc Nephrol.* 2004;15(2):241-50.
 6. Kafle MP, Shah SD, Shrestha S, Sigdel MR, Raut KB. Prevalence of specific types of kidney disease in patients undergoing kidney biopsy: a single centre experience. *Journal of Advances in Internal Medicine* 2014;03(01):5-10.
 7. Satirapoj B, Tasanavipas P, Supasyndh O. Clinicopathological correlation in asian patients with biopsy-proven lupus nephritis. *Int J Nephrol.* 2015;2015:857316.
 8. Shobha V, Prakash R, Arvind P, Tarey SD. Histopathology of lupus nephritis: A single-center, cross-sectional study from Karnataka, India. *IJRCI.* 2014;2(1):OA3.
 9. Schur PH, Berliner N. Hematologic manifestations of systemic lupus erythematosus in adults. In: UpToDate, Pissetsky DS, editor. Waltham, MA: UpToDate; 2017. <https://www.uptodate.com/contents/hematologic-manifestations-of-systemic-lupus-erythematosus-in-adults>
 10. Dhakal SS, Sharma SK, Bhatta N, Bhattarai S, Karki S, Shrestha S, et al. Clinical features and histological patterns of lupus nephritis in Eastern Nepal. *Saudi J Kidney Dis Transpl.* 2011;22(2):377-80.
 11. Esdaile JM, Levinton C, Federgreen W, Hayslett JP, Kashgarian M. The clinical and renal biopsy predictors of long-term outcome in lupus nephritis: a study of 87 patients and review of the literature. *Q J Med.* 1989;72(269):779-833.
 12. Tan EM, Cohen AS, Fries JF, Masi AT, McShane DJ, Rothfield NF, et al. The 1982 revised criteria for the classification of systemic lupus erythematosus. *Arthritis Rheum.* 1982;25(11):1271-7.
 13. Laman SD, Provost TT. Cutaneous manifestations of lupus erythematosus. *Rheum Dis Clin North Am.* 1994 Feb;20(1):195-212.
 14. Austin HA, 3rd, Boumpas DT, Vaughan EM, Balow JE. Predicting renal outcomes in severe lupus nephritis: contributions of clinical and histologic data. *Kidney Int.* 1994;45(2):544-50.
 15. Hahn BH. Systemic lupus erythematosus. In: Kasper DL, Braunwald E, Fouci AS, editors. *Harrison's Principles of Internal Medicine.* 18th ed. New York: McGraw-Hill; 2012. pp. 2724-35.
 16. Wallace JD. Diagnosis and differential diagnosis of systemic lupus erythematosus in adults. In: UpToDate, Pissetsky DS, editor. Waltham, MA: UpToDate; 2017.
 17. Malaviya AN, Singh RR, Kumar A, De A, Kumar A, Aradhya S. Systemic lupus erythematosus in northern India: a review of 329 cases. *J Assoc Physicians India.* 1988;36(8):476-80.