



ISSN: 2091-2749 (Print)
2091-2757 (Online)

Correspondence

Asst. Prof. Dr. Pooja Jaiswal,
Dept. of Radiology and Imaging,
Patan Academy of Health
Sciences, Lalitpur, Nepal
Email:
poojajaiswal@pahs.edu.np

Peer Reviewers

Prof. Dr. Rupesh Mukhiya
KIST Medical College, Nepal

Prof. Dr. Dipesh Kumar Yadav
The 1stHospital, Zhejiang Univ,
China

Submitted

10 Mar 2021

Accepted

15 Apr 2021

How to cite this article

Pooja Jaiswal, Shreejana
Shrestha, Yogita Dwa.
Comparison of ultrasound and
Contrast-enhanced computed
tomography in clinically
diagnosed cases of acute
pancreatitis. Journal of Patan
Academy of Health Sciences.
2021Apr;8(1):51-57.

<https://doi.org/10.3126/jpahs.v8i1.36864>

Comparison of ultrasound and Contrast-enhanced computed tomography in clinically diagnosed cases of acute pancreatitis

Pooja Jaiswal¹  , Shreejana Shrestha²  YogitaDwa¹ 

¹Asst. Prof., ²Assoc. Prof., Dept. of Radiology and Imaging, Patan Hospital, Patan Academy of Health Sciences, Lalitpur, Kathmandu, Nepal

Abstract

Introduction: Acute pancreatitis (AP) is an acute, mainly diffuse, inflammatory process of the pancreas with dynamic imaging characteristics and a multitude of possible complications. Imaging plays an important role in the diagnosis of AP. As most of the AP cases are gallstone-related, ultrasound (USG) is the most common initial radiologic investigation of choice. Contrast-enhanced CT (CECT) is the standard technique for overall assessment of AP and its complications. This study aims to compare diagnostic accuracy of imaging findings of USG with CECT.

Method: This was a retrospective review of imaging findings of USG and CECT in clinically diagnosed cases of AP who visited Radiology Department of Patan Hospital, Patan Academy of Health Sciences, Kathmandu, Nepal during 2015 to 2019 and had undergone USG and CECT. The diagnostic accuracy of USG and CECT imaging findings were compared. Study was approved ethically.

Result: Among 210 clinically diagnosed cases of acute pancreatitis, USG accurately diagnosed 97(46.2%), CECT 180(85.7%). Both the modalities detected cholelithiasis in 17% of the cases. Out of 97 cases, 85 showed focal or diffuse enlargement of pancreas on USG.

Conclusion: The CECT showed higher diagnostic accuracy for acute pancreatitis as compared to ultrasound, 85.7% vs. 46.2%. The overall visualization of the imaging features of AP and its complications was better by CECT than by USG

Keywords: acute pancreatitis (AP), ultrasound (USG), contrast-enhanced computed tomography (CECT)

Introduction

The incidence of acute pancreatitis (AP) continues to increase worldwide with an annual incidence rate of ranges from 13 to 45 per 100,000 population-years (0.013%-0.045%)¹ in parallel with an increasing demand on imaging modalities to diagnose and evaluate its severity.²⁻⁴ The mortality in severe AP can be as high as 30%⁵, however, the overall mortality in AP is estimated at 5%.⁶ Gallstones remain the most common cause for AP⁷; while, up to 25% of cases can be attributed to alcohol⁸ and 20-34% idiopathic. The incidence of idiopathic cases is similar in both men and women.⁹ Alcohol related pancreatitis is more common in the West and Japan compared with other Asian countries.^{10,11}

Imaging plays an important role in the diagnosis and management of AP. Ultrasound is an initial investigation of choice in the evaluation of pancreatitis, as it has various advantages: inexpensive, widely available, quick and easy to perform even at the bedside or in an intensive care environment, lack of radiation hazard and requires no intravenous contrast agents. It is about 95% sensitive in the detection of cholelithiasis and 50% sensitive for choledocholithiasis.¹² In AP, the pancreas is difficult to visualize during USG scan, due to its retroperitoneal location, overlying bowel gas, obesity, and epigastric tenderness.⁶

Contrast-enhanced CT (CECT) plays a role in establishing the diagnosis, staging the severity of the disease, and assists in the detection of complications.^{13,14} But non-availability of CECT in all health facilities and detection of AP is often compromised. So, this study aimed to assess the diagnostic accuracy of USG in comparison to CECT in clinically diagnosed cases of AP; to compare the imaging findings of AP by USG and CECT.

Method

This was a retrospective cross-sectional study conducted in the department of radiology and imaging between January 2015- December

2019 at Patan Hospital, Kathmandu, Nepal. Ethical permission was obtained from the institutional review committee of the Patan Academy of Health Sciences before the study.

The USG and CECT reports of all clinically diagnosed cases of AP were retrieved from the digital database of the radiology department and reviewed. All USGs were done in Philips Affinity 50/70 G machines with 3.5 MH convex probe; performed by the radiologists (MD Radio-Diagnosis and Imaging). All CECT examinations were performed in 128 slices Multi-Detector Computed Tomography (Injenuity, Philips). All the scans (USG and CECT) were viewed for the presence of AP, any associated aetiological factors like gallstone and its complications. Imaging findings included to evaluate the pancreas were the size of the pancreas, peripancreatic fat inflammation, peripancreatic fluid collection, pseudo pancreatic cyst, pancreatic necrosis, cholelithiasis, ascites, and other findings were pleural effusion.

Clinically diagnosed cases of AP in our study consisted following features: acute abdominal pain in the epigastric region of short duration and raised serum amylase, lipase levels.

The [Revised Atlanta classification](#) divides acute pancreatitis into two basic types: interstitial edematous pancreatitis (IEP) and necrotizing pancreatitis (NP).

Typical findings of IEP on USG/CECT are-

- normal-appearing pancreas with no peripancreatic abnormalities.
- focal or diffuse parenchymal enlargement: changes in parenchymal echotexture/density because of oedema, indistinct pancreatic margins owing to inflammation, surrounding retroperitoneal fat stranding.

Typical findings of NP on USG/CECT are-

- Necrosis of pancreatic parenchyma, peripancreatic necrosis, combined peripancreatic and parenchymal necrosis, abscess formation, calcification (later stages).

Imaging findings of USG and CECT scan in AP were compared. Data entry and analysis were done using IBM SPSS.

Result

A total of 210 AP patient’s USG and CT findings were reviewed. Males were 129(61%), 4/5th below the age of 60 y, Table 1.

In trans-abdominal USG, signs of AP were present among 97 participants, and in CECT

signs of AP were present among 180, Table 2, and Figure 1.

All the 97 patients diagnosed as AP by USG were also diagnose by CECT as AP. Out of, 97(46.2%) labeled as AP by USG, 85(87.62%) showed focal or diffuse enlargement of the pancreas, a prominent imaging feature in USG. When compared with CECT scan all reports (85) showed similar imaging findings. The diagnostic accuracy of USG vs. CECT showed CT was more accurate than USG, Figure 1.

Table 1. Demographics of acute pancreatitis (AP) patients (N =210)

Demographic Variables	N(%)
Male	129(61%)
Female	81(39%)
20–39 y	79(37.6%)
40-59 y	95(45.2%)
≥60 y	36(17.1%)

Table 2. Diagnosis of AP according to trans-abdominal USG & CECT (N=210)

Acute Pancreatitis	Trans-Abdominal USG, N(%)	CECT, N(%)
Present	97(46.2%)	180(85.7%)
Absent	113(53.8%)	30(14.3%)

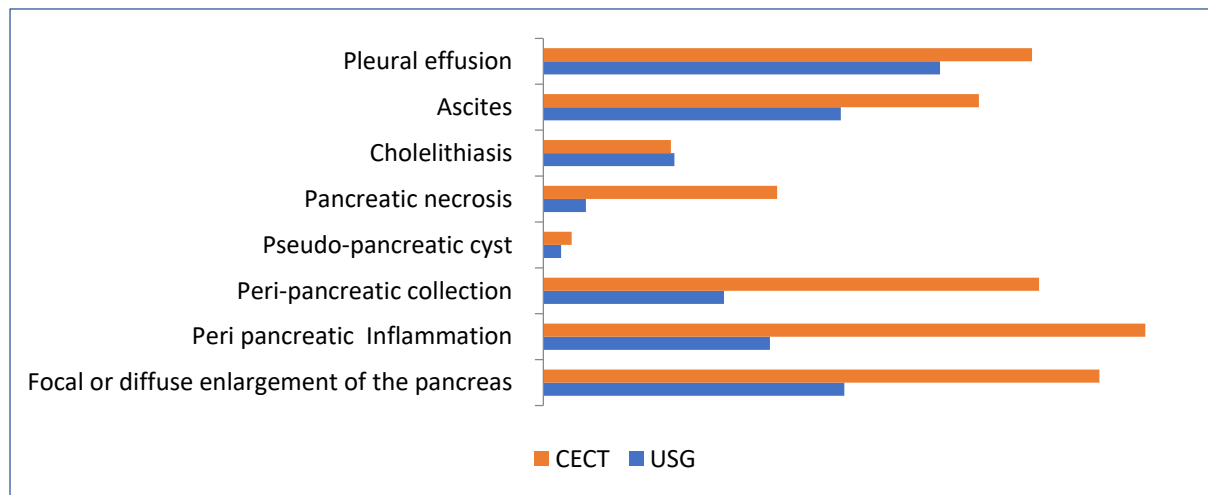


Figure 1. Comparison between USG & CECT findings of acute pancreatitis (N=210)

Discussion

In our study, USG detected 46.2% of cases, and CECT, which is considered as the gold standard, detected 85.7% of clinically diagnosed AP.

The study done in Tripura, India showed 60% imaging features of AP in USG,¹⁵ which is similar to our study findings. However, the study was done in Bhubaneswar, India,¹⁶ showed 83.3% AP in USG imaging features and

80% in CECT. As mentioned in one of the studies, a negative ultrasound study does not exclude pancreatic disease.¹⁷ The CECT could visualize and confirm the imaging features consistent with AP in all the patients in which USG had shown features of AP.

The variations in imaging features of USG in different studies suggested technique dependence on the operator's expertise and quality of equipment and the time of the scan. The success rate of USG also decreases with obesity and overlying bowel gas in unprepared patients and an increase in severity of the disease. Similarly, the diagnostic accuracy in detection of imaging features of AP in CECT increases with the increased number of slices.

In the present study, CECT visualization of the pancreas was possible in all 210(100%) cases. The overall visualization of the pancreas was far better by CECT than by USG in our study.

A satisfactory detection of AP by CECT was reported in 98% of examinations¹⁸ which was 85.7% in our study. Imaging features of AP on CECT also depend on the severity of pancreatitis. In mild pancreatitis, the CT features ranges from a normal-appearing pancreas with no peripancreatic abnormalities to diffuse enlargement of the pancreas, peripancreatic inflammation, and stranding into surrounding fat.¹⁹

In our study 129 patients were male and 81 females, suggesting AP occurring nearly 2.5 times more common in males (M:F=2.5:1). This coincides with western literature²⁰ and similar Indian studies.¹⁵ Pancreatitis in women is mostly gallstones related.²¹ The increasing incidence of obesity indirectly causes AP because obesity promotes gallstone formation, which is one of the commonest causes of AP. However, alcohol related pancreatitis is more common in men, although sex differences disappear with similar levels of alcohol consumption.²²

Nearly half the number of the patients (45.2%) in our study were between 40 to 60 y which was similar to the Indian study;¹⁵ however, in

another study it was more common in 30 to 50 y.²³ Age of the patients is also important because according to one study²⁴, the mortality of the disease increases with age, particularly in patients above 60 y.

In our study, out of 210 patients who had undergone USG, we did not find AP in 113(53.8%) and were detected by CECT. Those 113 reports were unsatisfactory for evaluation of the pancreas by USG. The pancreas and the surrounding areas are difficult to visualize often in USG, due to poor penetration of high frequency sound waves in big-built patients and the presence of excessive bowel gas. These limitations of USG compromise the quality of the scan which was supported also by another study.²⁵

USG has low sensitivity in identifying peripancreatic collections and pancreatic necrosis. The CECT appearance of peripancreatic collections depends on its stage of involvement. Acute or early collections are seen as a poorly marginated focal collection within the pancreatic parenchyma. As they mature, they become well marginated with a discernible wall or capsule. In our study, USG could identify peripancreatic collections in 51(24.3%) compared to 140(66.7%) on CECT, making CECT superior in evaluation of complication of AP, which is fairly correlating with a study conducted in AIIMS in 2015.¹⁸ Pancreatic necrosis in USG was seen in 12(5.7%) as compared to 66(31.4 %) on CECT.

However, USG is very useful particularly for the evaluation of cholelithiasis. In our study, cholelithiasis was present in 36(17%) patients, both on USG and CECT, and enlargement in the size and peripancreatic inflammation were the most common USG findings in our study.

In CECT, pancreatic necrosis appears as areas of low density in the pancreas at an early stage of the disease.²⁶ In our study, CECT showed features of pancreatic necrosis in 66(31.4%) patients whereas USG could identify it only in 12(5.7%), so CECT was superior in this respect. Similarly, a study done in Bhubaneswar, India¹⁶

showed 26% of patients had pancreatic necrosis which was not shown by USG.

The major advantage of CECT is its sensitivity for AP for accurate assessment of the pancreas and extent of inflammation along various anatomical planes.²⁷ The typical CECT appearance includes diffuse enlargement of the gland, decreased central density producing a sac-like configuration.²⁷ In our study, peripancreatic inflammation was observed in 170(81%) cases, which is much higher than the reported incidence of 25%.²⁷ Detection of peripancreatic inflammation by CECT depends largely on the number of a slice of CT. This could be due to the number of slices, we used 128 slice CT.

In our study, pseudocyst, one of the complications of AP was visualized in 5(2.4%) cases by USG and 8(3.8%) by CECT. The appearance of complications depends upon the severity and timing of the scan in disease progression, as well as user expertise.

The study done in Tripura, India showed 60% imaging features of AP in USG¹⁵ similar to our study findings. However, the study was done in Bhubaneswar, India,¹⁶ showed 83.3% AP in USG imaging features and 93% in CECT.

As mentioned in a study, a negative ultrasound study does not exclude pancreatic disease¹⁷, but USG had a positive predictive value of 100%. Also in our study, CECT confirmed features of AP in all the patients in which USG had shown features of AP.

Comparing both the diagnostic modalities described above, it was found that the CECT scan has the highest accuracy rate 85.7% in the present study in detecting AP, with other studies¹⁶ showing 80% AP in USG imaging features and 83.3% in CECT.

The main role of USG in the imaging of AP is in the detection of the size of the pancreas, biliary stones, fluid collections in the peritoneum and pleural spaces. Also, USG is easily accessible and non-invasive radiation-free in nature. It is less time-consuming, and in

emergencies when the patients' conditions are unstable and declining, USG can be used as an initial diagnostic tool. But in the majority of patients in the present study, USGs were either suboptimal or difficult to visualize the pancreas. This leads to a diagnostic challenge and subsequent CT scan becomes essential and important.

The key role of CT scan is to determine the inflammation of the pancreas in which USG was unable to diagnose or sub-optimally examined. Also, it plays a major role to determine the extent of the affected gland, multisystem involvement, and complications as early diagnosis and management become critical to avoid severe consequences of pancreatitis.

Indications to perform a CT varies among different institutions in different geographic areas and are largely dictated by local preferences and cost factors. Some advocate performing CT on admission for staging purposes and improved patient care.^{28,29}

Our study shows, CECT is a confirmative investigation in diagnosis and determining the severity. However, the USG is the initial choice of investigation in the evaluation of AP due to its main role in detecting biliary calculi. Early identification and treatment of these calculi may have a significant positive impact on the outcome. The limitations of USGs can be overcome with the use of CT yielding more diagnostic information. The CECT showed better delineation and extent of the disease than USG. However, USG has an immense role in the early and initial diagnosis of AP in resource limited healthcare settings, where CECT is not readily available and cannot be done in certain patients due to medical limitations. Thus, we can conclude that both USG and CECT have roles to play in the diagnosis of AP and both are complementary to each other.

Limitations, of our study, could be different USG operators (doctors), most of the patients were referred from the emergency

department who were not prepared (no bowel preparation and no fasting).

Conclusion

The CECT showed higher diagnostic accuracy for acute pancreatitis as compared to ultrasound, 85.7% vs. 46.2%. The overall visualization of the imaging features of AP and its complications was better by CECT than by USG.

Conflict of Interest

None

Funding

None

Author Contribution

Concept, design, planning- PJ; Literature review- PJ, SS, YD; Data collection/analysis- PJ; Draft manuscript- PJ; Revision of draft- PJ, SS, YD; Final manuscript- PJ, SS, YD; Accountability of the work- PJ, SS, YD.

Reference

- Yadav D, Lowenfels AB. The epidemiology of pancreatitis and pancreatic cancer. *Gastroenterology*. 2013;144(6):1252-61. | [DOI](#) | [PubMed](#) | [Google Scholar](#) | [Weblink](#) |
- Thoeni RF. Imaging of Acute pancreatitis. *Radiol Clin North Am*. 2015;53(6):1189-208. | [DOI](#) | [PubMed](#) | [Google Scholar](#) | [Weblink](#) |
- Thoeni RF. The revised Atlanta classification of acute pancreatitis: its importance for the radiologist and its effect on treatment. *Radiology*. 2012;262(3):751-64. | [DOI](#) | [PubMed](#) | [Google Scholar](#) | [Weblink](#) |
- Bollen TL. Imaging of acute pancreatitis: update of the revised Atlanta classification. *Radiol Clin North Am*. 2012;50(3):429-45. | [DOI](#) | [PubMed](#) | [Google Scholar](#) | [Weblink](#) |
- Whitcomb DC. Acute pancreatitis. *N Engl J Med*. 2006;354(20):2142-50. | [DOI](#) | [PubMed](#) | [Google Scholar](#) | [Weblink](#) |
- Toouli J, Brooke-Smith M, Bassi C, Carr-Locke D, Telford J, Freeny P, et al. Guidelines for the management of acute pancreatitis. *J Gastroenterol Hepatol*. 2002;17 Suppl:S15-39. | [DOI](#) | [PubMed](#) | [Google Scholar](#) | [Weblink](#) |
- Kingsnorth A, O'Reilly D. Acute pancreatitis. *BMJ*. 2006;332(7549):1072-6. | [DOI](#) | [PubMed](#) | [Weblink](#) |
- National Institute for Health and Care Excellence. Pancreatitis: diagnosis and management draft scope for consultation. London: National Institute for Health and Clinical Excellence; 2016. 12p. | [Full Text](#) |
- Yadav D, Lowenfels AB. Trends in the epidemiology of the first attack of acute pancreatitis. *Pancreas*. 2006;33(4):323-30. | [DOI](#) | [PubMed](#) | [Google Scholar](#) | [Weblink](#) |
- Mohan V, Farooq S, Deepa M. Prevalence of fibrocalculous pancreatic diabetes in Chennai in South India. *JOP*. 2008;9(4):489-92 | [PubMed](#) | [Google Scholar](#) | [Full Text](#) |
- Balaji LN, Tandon RK, Tandon BN, Banks PA. Prevalence and clinical features of chronic pancreatitis in southern India. *Int J Pancreatol*. 1994;15(1):29-34. | [DOI](#) | [PubMed](#) | [Google Scholar](#) | [Weblink](#) |
- Surlin V, Saftoiu A, Dumitrescu D. Imaging tests for accurate diagnosis of acute biliary pancreatitis. *World J Gastroenterol*. 2014;20(44):16544-9. | [DOI](#) | [PubMed](#) | [Google Scholar](#) | [Weblink](#) |
- Balthazar EJ. Acute pancreatitis: assessment of severity with clinical and CT evaluation. *Radiology*. 2002;223(3):603-13. | [DOI](#) | [PubMed](#) | [Google Scholar](#) | [Weblink](#) |
- Balthazar EJ. CT diagnosis and staging of acute pancreatitis. *Radiol Clin North Am*. 1989;27(1):19-37. | [PubMed](#) | [Google Scholar](#) |
- Debbarma B, Tripura K. A study on diagnostic accuracy of biochemical markers and trans-abdominal ultrasonography in comparison to multi-detector computed tomography in detection of acute pancreatitis. *Journal of Evolution of Medical and Dental Sciences*. 2016;5(60):4181. | [Google Scholar](#) | [Full Text](#) | [Weblink](#) |
- Panda S, Tirkey R, Swain BM, Jena S, Sarangi AK, Sarangi A. Acute pancreatitis, its diagnosis with special reference to contrast enhanced CT scan (CECT) and serum enzyme studies: a comparative study in tertiary referral hospital of Odisha, India. *Intl Surg J*. 2017;4(12):4022-8. | [DOI](#) | [Google Scholar](#) | [Full Text](#) | [Weblink](#) |
- Hessel SJ, Siegelman SS, McNeil BJ, Sanders R, Adams DF, Alderson PO, et al. A prospective evaluation of computed tomography and ultrasound of the pancreas. *Radiology*. 1982;143(1):129-33. | [DOI](#) | [PubMed](#) | [Google Scholar](#) | [Weblink](#) |
- Garg PK, Imrie CW. Severity classification of acute pancreatitis: the continuing search for a better system. *Pancreatol*. 2015;15(2):99-100. | [DOI](#) | [PubMed](#) | [Google Scholar](#) | [Weblink](#) |

19. Maher MM, Lucey BC, Gervais DA, Mueller PR. Acute pancreatitis: the role of imaging and interventional radiology. *Cardiovasc Intervent Radiol.* 2004;27(3):208-25. | [DOI](#) | [PubMed](#) | [Google Scholar](#) | [Weblink](#) |
20. Marks IN, Bank S. The aetiology, clinical features and diagnosis of pancreatitis in the south-western Cape; a review of 243 cases. *S Afr Med J.* 1963;37:1039-53. | [PubMed](#) | [Google Scholar](#) | [Full Text](#) |
21. Garg PK. Chronic pancreatitis in India and Asia. *Curr Gastroenterol Rep.* 2012;14(2):118-24. | [DOI](#) | [PubMed](#) | [Google Scholar](#) | [Weblink](#) |
22. Lankisch PG, Lowenfels AB, Maisonneuve P. What is the risk of alcoholic pancreatitis in heavy drinkers? *Pancreas.* 2002;25(4):411-2. | [DOI](#) | [PubMed](#) | [Google Scholar](#) | [Weblink](#) |
23. Fan ST, Lai EC, Mok FP, Lo CM, Zheng SS, Wong J. Early treatment of acute biliary pancreatitis by endoscopic papillotomy. *N Eng J Med.* 1993;328(4):228-32. | [DOI](#) | [PubMed](#) | [Google Scholar](#) | [PDF](#) | [Weblink](#) |
24. Trapnell JE. Acute pancreatitis. *Proc R Soc Med.* 1972;65(10):846-7. | [PubMed](#) | [Full Text](#) |
25. Ammann RW, Buehler H, Bruehlmann W, Kehl O, Muench R, Stamm B. Acute (non-progressive) alcoholic pancreatitis: prospective longitudinal study of 144 patients with recurrent alcoholic pancreatitis. *Pancreas.* 1986;1(3):195-203. | [PubMed](#) | [Google Scholar](#) |
26. Block S, Maier W, Bittner R, Buchler M, Malferteiner P, Begner HG. Identification of pancreas necrosis in severe acute pancreatitis: imaging procedures versus clinical staging. *Gut.* 1986;27(9):1035-42. | [DOI](#) | [PubMed](#) | [Google Scholar](#) | [Weblink](#) |
27. White EM, Wittenberg J, Mueller PR, Simeone JF, Butch RJ, Warshaw AL, et al. Pancreatic necrosis: CT manifestations. *Radiology.* 1986;158(2):343-6. | [DOI](#) | [PubMed](#) | [Google Scholar](#) | [Weblink](#) |
28. Pocard M, Soyer P. CT of acute pancreatitis: a matter of time. *Diagn Interv Imaging.* 2015;96(2):129-31. | [DOI](#) | [PubMed](#) | [Google Scholar](#) | [Weblink](#) |
29. Vriens PW, van de Linde P, Slotema ET, Warmerdam PE, Breslau PJ. Computed tomography severity index is an early prognostic tool for acute pancreatitis. *J Am Coll Surg.* 2005;201(4):497-502. PMID: 16183486 | [DOI](#) | [PubMed](#) | [Google Scholar](#) | [Weblink](#) |