



ISSN: 2091-2749 (Print)  
2091-2757 (Online)

#### Correspondence

Dr. Surya Bahadur Thapa  
Department of Orthopaedics  
C P Hospital, Dhangadi  
Nepal  
Email:  
suryathapa145@gmail.com

#### Peer Reviewers

Prof. Dr. Nabees Man Singh  
Pradhan, Patan Academy of  
Health Sciences

Prof. Dr. Jay Narayan Shah  
Patan Academy of Health  
Sciences

#### Submitted

16 Jul 2018

#### Accepted

28 Nov 2018

#### How to cite this article

Surya Bahadur Thapa. Delayed recognition of osteoarticular infection of left humerus and ipsilateral shoulder joint: a case report. Journal of Patan Academy of Health Sciences. 2018Dec;5(2):66-69.

## Delayed recognition of a case of osteoarticular infection of left humerus and ipsilateral shoulder joint

Surya Bahadur Thapa

Department of Orthopaedics, C P Hospital, Dhangadi, Nepal

### Abstract

Osteoarticular infection of humerus and shoulder joint are uncommon. Prompt diagnosis and management of acute osteoarticular infection with early antibiotic and sometimes surgery is required to prevent chronic osteomyelitis and sequelae of septic arthritis. This case illustrates how a treatable case of acute osteoarticular infection was missed and progressed to chronic osteomyelitis. The aim of reporting this case is to present a rare site of osteoarticular infection of humerus and shoulder joint was complicated due to failure in recognition and management.

**Keywords:** chronic osteomyelitis, humerus and shoulder joint, osteoarticular infection, pediatrics

## Introductions

Osteomyelitis of long bones in pediatric population is common ranging from 2.5-75/10,000; but, osteoarticular infection of humerus and ipsilateral shoulder joint is less common 5-35/10,000.<sup>1,2</sup> Despite osteoarticular infection of humerus and shoulder joint being less common, manifestation of the disease is similar like in osteomyelitis of other bones. Here, we present a case of delay in prompt diagnosis and treatment, which may result in complications and chronic osteomyelitis, lifelong troublesome sequelae.

## Case Report

A boy of 11 years presented in emergency with pain and swelling around the left shoulder and arm for 10 days. He had a history of carrying load on this shoulder for 30 minutes before onset of symptoms. There was no significant history of trauma. The child had a past history of recurrent multiple abscesses in skin and was treated at home. He was diagnosed with soft tissue injury in a primary level hospital. The child was managed with rest and analgesics for soft tissue injury of the shoulder. His symptoms worsened and came to us for further management.

He looked ill but afebrile. Locally there was a marked swelling, raised temperature, severe

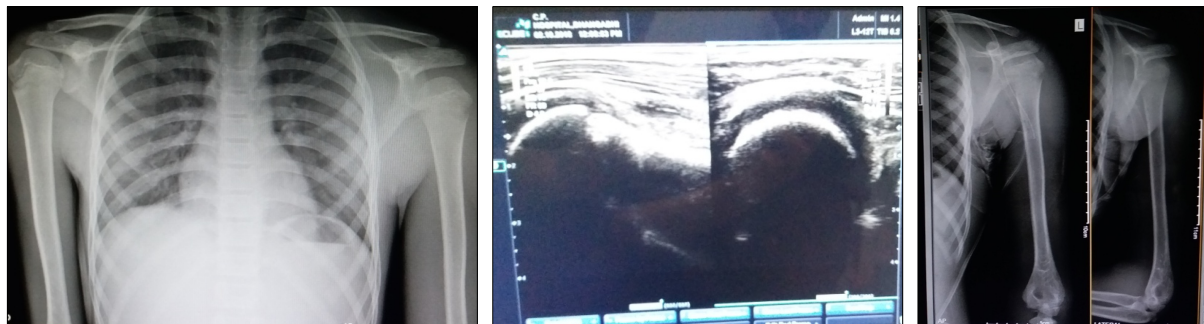
tenderness and reduced range of motion of left shoulder joint.

His White Blood Cell (WBC) count was 20,000/mm<sup>3</sup> with Neutrophils 86% and erythrocyte sedimentation rate (ESR) 50 mm/hour. The X-ray of left shoulder joint and humerus showed inferiorly subluxed humeral head (Figure 1) and normal looking humerus. The ultrasonography (USG) revealed fluid collection inside left shoulder joint, (Figure 2).

Emergency arthrotomy and decompression of left proximal humerus was done with the diagnosis of osteoarticular infection of humerus and septic arthritis of the ipsilateral shoulder joint. On 5<sup>th</sup> postoperative day, he required incision and drainage for subperiosteal pus collection of left distal humerus.

Histopathology was consistent with chronic osteomyelitis of left humerus. Staphylococcus aureus grew in culture. It was sensitive to ceftriaxone and cefixime. He received intravenous ceftriaxone for two weeks and gentamycin for five days. He was discharged home on oral cefixime for four weeks.

In two weeks followup, he had glenohumeral range of motion of 100 degrees flexion and 100 degrees of abduction. There was periodic scanty pus discharge from the sinus formed at the drain site.



**Figure 1. X-ray of both shoulder anteroposterior (AP) view, showing increased acromiohumeral distance suggesting inferiorly subluxed humeral head on the left side**

**Figure 2. Ultrasonography showing echogenic collections inside left shoulder joint**

**Figure 3. X-ray left shoulder AP/lateral view showing reduced inferiorly subluxed humeral head**

## Discussions

Our case of osteoarticular infection of left humerus and ipsilateral shoulder joint following history of carrying load on shoulder was not timely recognized of impending traumatic osteomyelitis in a primary level hospital. Unspecific presentation in early phase without obvious history of trauma or only a trivial trauma leads to wrong diagnosis like soft tissue injury, as in our case.<sup>3</sup> Recurrent history of skin infection in the past suggests that he was possibly a chronic carrier of bacteria and had hematogenous spread of bacteria in this case. Osteomyelitis spreads via hematogenous route, direct inoculation after trauma or during surgery.

Hair loop-shaped capillaries leading to stasis of blood flow, rarity of macrophages and low oxygen tension make metaphysis prone for infection. The infection of metaphysis in the humerus inside the capsule leads to involvement of shoulder joint as well.<sup>4</sup> Staphylococcus aureus is the commonest organism for septic arthritis. Other pathogens are staphylococcus epidermidis, enterobacter species and rarely fungus and Salmonella. Patients with methicillin-resistant staphylococcus aureus (MRSA) have severe disease due to panto-valentine leukocidin (PVL).<sup>5</sup>

Diagnosis of osteomyelitis requires cumulative information of history, clinical examination, laboratory reports and imaging.<sup>6</sup> Laboratory reports (WBC, ESR, and c-reactive protein- CRP) are non-specific. The X-ray takes 10-21 days to show bone destruction and periosteal reaction. Negative films do not exclude the diagnosis of osteomyelitis. In cases of septic arthritis, there may be subluxation due to joint distention with fluid collection (Figure 1, 2, 3). The magnetic resonance imaging (MRI) is a choice of investigation. Bone marrow edema is the earliest feature in MRI as early as 1 to 2 days after onset of infection. It produces low signal on T1W and high signal on fluid sensitive and post contrast sequences. The USG shows

subperiosteal collections and collection inside the joint, soft tissue edema and hyper-vascularity in color doppler and aids in needle aspiration. Triple phase bone scan (angiographic/tissue/osseous) are helpful to discern cellulitis from osteomyelitis in non-violated bone. In cellulitis, there is higher uptake in only two phases; and osteomyelitis have higher uptake in all the three phases. In cases of violated bone, white cell scans are available but it needs further imaging to discern infection from normal physiological white cell uptake. The computed tomography (CT) is unable to demonstrate marrow edema, and normal CT does not rule out osteomyelitis.<sup>7</sup> Gold standard for diagnosis of osteoarticular infection is bone biopsy with histopathologic examination and tissue culture.<sup>8</sup> Articular fluid culture yield is 42.49 % in septic arthritis and 52.65% in osteomyelitis.<sup>6</sup>

The treatment for osteoarticular infection is antibiotics and surgery. For *S. aureus*, choice of antibiotics are clindamycin, first generation cephalosporins and vancomycin. Where MRSA is not a concern, anti-staphylococcal penicillin or first-generation cephalosporin is recommended because they also cover other causes of hematogenous osteomyelitis including streptococcus pyogenes and *Kingella kingae* in pediatric age group three months or older. The intravenous antibiotic is given for 7-14 days until child responds clinically and CRP returns to base line. Then oral antibiotic is continued for 4-6 weeks until normalization of ESR. Incision and drainage for abscess (intra-osseous, sub-periosteal or soft tissue), debridement, arthroscopy, needle aspiration and arthrotomy are surgical methods of treatment of osteoarticular infection.<sup>9</sup>

Complications range from early septicemia to death or long-term disability. Long-term complications are upper limb length discrepancy, pandoaphyseal osteomyelitis, septic dislocation of shoulder joint, joint stiffness and osteonecrosis of humeral head.

## Conclusions

Our case report shows high index of suspicion is required for early diagnosis and treatment of osteoarticular infection for successful outcome as investigation are not always confirmative.

## References

1. Ilyas AM, Mudgal CS. Management of medullary osteomyelitis of the humerus. *Tech Hand Up Extrem Surg.* 2008;12(3):144-9. DOI: 10.1097/BTH.0b013e31816d1fa5 PMID:31T 1877677431T [GoogleScholar](#)
2. Stoesser N, Pocock J, Moore CE, Soeng S, et al. The epidemiology of pediatric bone and joint infections in Cambodia, 2007-11. *J Trop Pediatr.* 2013;59(1):36-42. DOI: 10.1093/tropej/fms044 31T
3. Mallia AJ, Ashwood N, Arealis G, Bindi F, Zamfir G, Galanopoulos I. Delayed recognition of pediatric calcaneal osteomyelitis: a case report. *J Med Case Rep.* 2015;9:185. DOI: 10.1186/s13256-015-0657-x
4. Stott NS. Review article: paediatric bone and joint infection. *J Orthop Surg (Hong Kong).* 2001;9(1):83-90. DOI: 10.1177/230949900100900116
5. Adkins T, Rees M, Simeone F, Isaacs R, Halsell A, Flowers ER. Case records of the Department of Medicine University of Mississippi Medical Center. Histoplasma capsulatum osteomyelitis humerus, metastatic pulmonary histoplasmosis. *J Miss State Med Assoc.* 1994;35(3):59-64. PMID: 8182736
6. Russell CD, Ramaesh R, Kalima P, Murray A, Gaston MS. Microbiological characteristics of acute osteoarticular infections in children. *J Med Microbiol.* 2015;64(Pt 4):446-53. DOI: 10.1099/jmm.0.00002631T PMID: 25596125
7. Pineda C, Espinosa R, Pena A. Radiographic imaging in osteomyelitis: the role of plain radiography, computed tomography, ultrasonography, magnetic resonance imaging, and scintigraphy. *Semin Plast Surg.* 2009;23(2):80-9. DOI: 10.1055/s-0029-121416031T PMID: 20567730
8. Fritz JM, McDonald JR. Osteomyelitis: approach to diagnosis and treatment. *Phys Sportsmed.* 2008;36(1):50-4. DOI: 10.3810/psm.2008.12.11
9. Harik NS, Smeltzer MS. Management of acute hematogenous osteomyelitis in children. *Expert Rev Anti Infect Ther.* 2010;8(2):175-81. DOI: 10.1586/eri.09.130 PMID: PMC2836799